

Minimally Invasive Parathyroidectomy Using Cervical Block

Reasons for Conversion to General Anesthesia

Tobias Carling, MD, PhD; Patricia Donovan, RN;
Christine Rinder, MD; Robert Udelsman, MD, MBA

Hypothesis: We investigated the frequency and reasons for conversion from cervical block anesthesia to general anesthesia (GA) in patients undergoing minimally invasive parathyroidectomy for primary hyperparathyroidism.

Design: Prospective case series.

Setting: Tertiary university hospital.

Patients: A total of 441 consecutive patients with primary hyperparathyroidism undergoing minimally invasive parathyroidectomy under cervical block and monitored anesthesia care using midazolam and narcotics were included. Patients with known multiglandular, familial, or secondary hyperparathyroidism or noninformative preoperative localization or those electing minimally invasive parathyroidectomy under GA were excluded.

Intervention: All patients underwent cervical block anesthesia and focused exploration using minimally invasive techniques.

Main Outcome Measure: Intraoperative need for conversion from cervical block anesthesia to general endotracheal anesthesia.

Results: Of the 441 patients, 47 (10.6%) required conversion to GA. In all instances, conversion was performed in a controlled fashion using neuromuscular blockade, endotracheal intubation, and maintenance of the original surgical field preparation. Sixteen procedures were converted to accomplish simultaneous thyroid resections. An additional 15 were converted because the intraoperative parathyroid hormone level failed to decrease by at least 50% from the baseline after resection of the incident parathyroid tumor and extensive exploration was required. Eight procedures were converted because of technical difficulties related to ensuring adequate protection of the recurrent laryngeal nerve. Five procedures were converted to optimize patient comfort, and 2 were converted because of the intraoperative recognition of parathyroid carcinoma. One patient experienced a toxic reaction to lidocaine, causing a seizure.

Conclusions: The vast majority of minimally invasive parathyroidectomies can be performed using cervical block anesthesia. However, conversion to GA is appropriate when unexpected intraoperative findings are encountered or for patient comfort.

Arch Surg. 2006;141:401-404

Author Affiliations:
Department of Surgery and
Anesthesiology (Dr Rinder),
Yale University School of
Medicine (Drs Carling and
Udelsman and Ms Donovan),
New Haven, Conn.

P RIMARY HYPERPARATHYROIDISM (HPT) is common, especially in elderly women, and health-screening examinations suggest a prevalence of up to 2.1% in postmenopausal women.¹ Primary HPT of nonfamilial origin can be attributed to a benign, single adenoma in 80% of cases, to multiglandular parathyroid hyperplasia in 15% to 20% of cases, and rarely to parathyroid carcinoma.² Surgery is the only available curative treatment.

Bilateral neck exploration under general anesthesia (GA) with intraoperative frozen-section histopathologic examination of excised parathyroid tissue identifying all parathyroid glands has been the

preferred surgical management of primary HPT.³ However, because of the advancements in preoperative localization, availability of intraoperative parathyroid hormone (PTH) measurement, and the fact that most patients with primary HPT have a unilateral parathyroid adenoma, minimally invasive parathyroidectomy (MIP) techniques have been developed.³⁻⁹ The MIP technique has become the standard of care in institutions with significant experience with the procedure.^{3,5,10} Detailed follow-up of 656 consecutive parathyroid explorations shows that the success rate is 99% with the MIP technique vs 97% with the conventional technique.⁵ Also, the time to hospital discharge and costs are significantly reduced.⁵

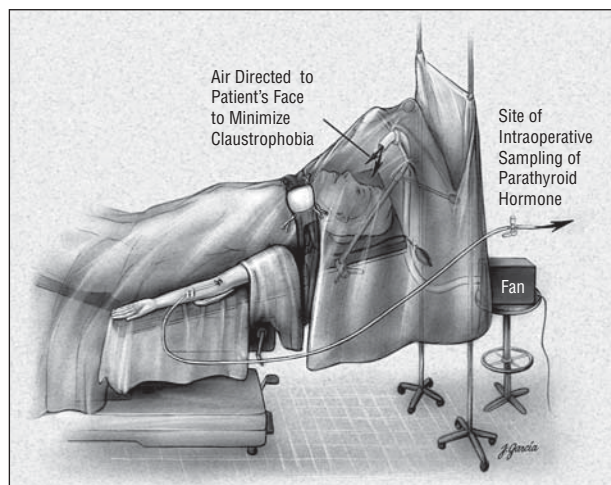


Figure 1. The patient has a large-bore peripheral intravenous catheter inserted, which is used for medication and fluid administration as well as sampling for parathyroid hormone levels. The patient is awake, and a fan is used to blow room air gently toward his or her face to minimize the sensation of claustrophobia. Reprinted with permission from *Minimally Invasive Endocrine Surgery*.¹¹ Copyright 2002, Lippincott Williams & Wilkins.

The MIP technique used at our institution is generally performed with the patient awake, using surgeon-administered cervical block and monitored anesthesia care.^{3,11} However, in some instances, conversion to GA is performed. This study analyzes 441 consecutive cases of MIP under cervical block anesthesia and frequency and reason for conversion to general endotracheal anesthesia.

METHODS

Between January 2000 and April 2004, 441 consecutive patients with primary HPT underwent MIP under cervical block and monitored anesthesia care using midazolam and narcotics. All patients underwent preoperative localization studies either with technetium Tc 99-labeled sestamibi with single-photon emission computed tomography imaging⁶ and, in some instances, sonography. Patients with known multiglandular, familial, or secondary HPT; those electing MIP under GA; or those in which the preoperative localization study results were negative were excluded.

The MIP technique used at our institution has been described elsewhere.^{3,11} Briefly, the procedure is performed with the patient awake but under monitored anesthesia care using midazolam and narcotics (**Figure 1**). The superficial cervical block was administered on the ipsilateral side of the prelocalized parathyroid lesion. In most patients, a total volume of 20 mL of 1% lidocaine with 1:100 000 epinephrine was used (**Figure 2**). Supplementation of local anesthesia and intravenous sedatives was used when required. The amount of intravenous sedatives used during MIP was generally low and used after discussions between the anesthesiologist, the surgeon, and the individual patient. Typically, approximately 2 to 5 mg of midazolam and 2 to 5 mg of morphine or other opioid was used. Surgical exploration was performed as previously described.⁶ Briefly, the approach is individualized based on the preoperative localization of the parathyroid adenoma. Typically, a 2.5- to 4.0-cm, abbreviated Kocher incision is made, and the parathyroid adenoma is identified and excised after the creation of limited subplatysmal flaps and mobilization of the ipsilateral strap muscles. The recurrent laryngeal nerve is carefully protected throughout the procedure.

Intraoperative intact PTH measurement in peripheral blood was used. A decline of more than 50% in PTH level was used as an indication of cure, and no additional exploration was performed.¹² Failure of the plasma PTH level to adequately decline suggested remaining hyperfunctioning parathyroid tissue and additional surgery was indicated.

RESULTS

The clinical characteristics of the 441 consecutive patients with primary HPT undergoing MIP are presented in **Table 1**. Of the 441 patients, 47 (10.6%) required conversion to GA. In all instances, conversion was performed in a controlled fashion using neuromuscular blockade, endotracheal intubation, and maintenance of the original surgical field preparation.

Sixteen procedures were converted to accomplish simultaneous thyroid resections owing to concomitant thyroid pathologic features (**Table 2**). Of the 16 patients, 12 had benign adenomas, 3 had well-differentiated thyroid cancer confined to the thyroid, and 1 exhibited papillary thyroid cancer with local level VI lymph node metastases. An additional 15 patients were converted because the intraoperative PTH level failed to decrease by at least 50% from the baseline after resection of the incident parathyroid tumor and extensive exploration was required, identifying 2 enlarged glands or "double adenomas" in 6 cases, whereas the remaining patients had primary parathyroid hyperplasia. In all these instances, additional parathyroid pathologic features were identified and resected, with an ensuing appropriate decrease in the intraoperative PTH levels. Eight procedures were converted because of technical difficulties related to ensuring adequate protection of the recurrent laryngeal nerve. Five procedures were converted to optimize patient comfort. In 2 instances, conversions were owing to intraoperative recognition of parathyroid carcinoma, which was treated with en bloc resection with ipsilateral hemithyroidectomy. One patient experienced a toxic reaction to lidocaine, causing a seizure. Although transient inadvertent blockade of other nerves (eg, vagus, brachial plexus) rarely occurred, there were no other complications of the cervical block.

Of the 47 patients, 45 (95.7%) were normocalcemic at a mean \pm SEM follow-up of 9 ± 0.01 months. One patient had persistent hypercalcemia, whereas 1 patient with parathyroid cancer had recurrent disease. One patient developed severe hypocalcemia.

COMMENT

The standard technique for parathyroid exploration includes bilateral cervical exploration with the goal of identifying all parathyroid glands.^{3,5} This procedure usually involves GA, although it has been performed with bilateral regional cervical block. The objective of identifying all parathyroid glands is to differentiate between uniglandular and multiglandular HPT. Patients with a parathyroid adenoma will undergo curative resection when the adenoma is excised. In patients with multiglandular disease, a total parathyroidectomy with immediate het-

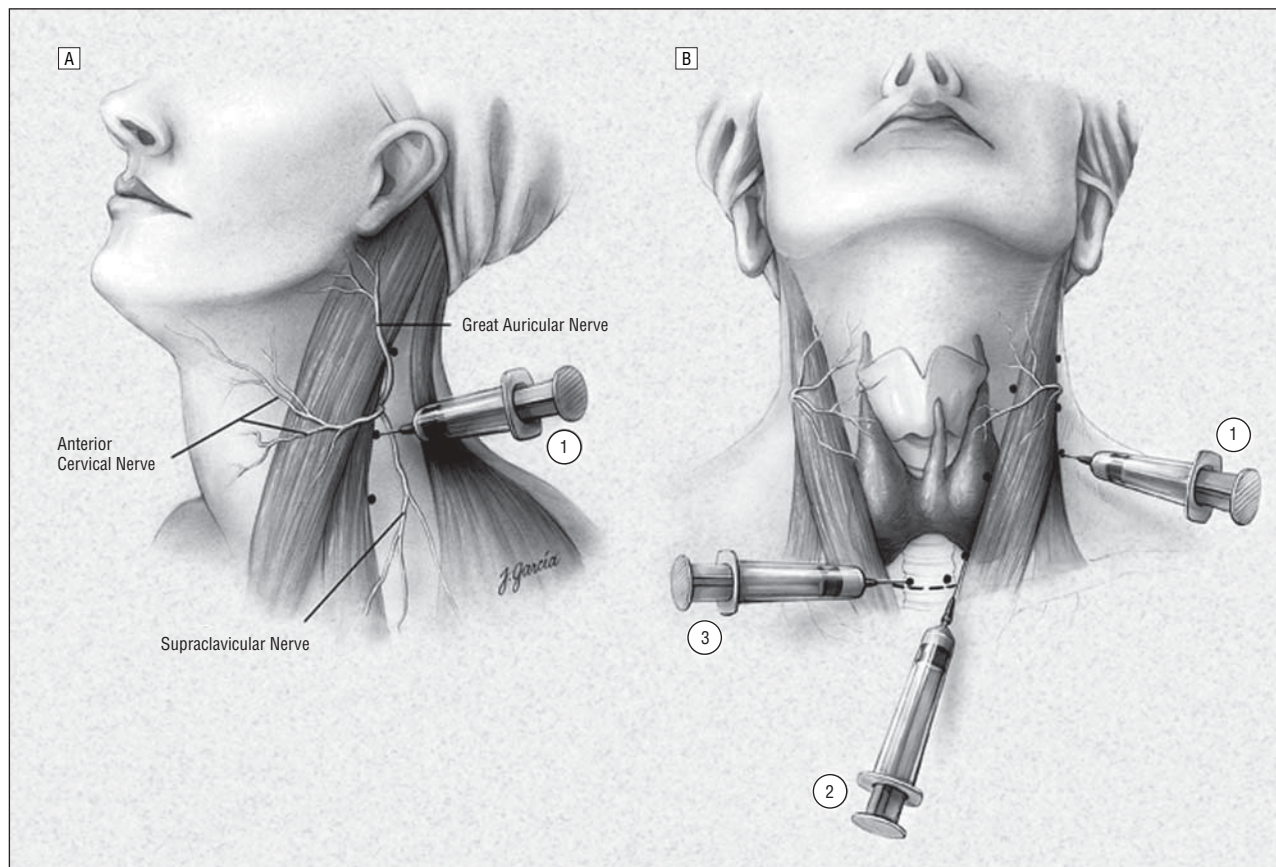


Figure 2. Cervical block anesthesia. A, A superficial cervical block is administered posterior and deep to the sternocleidomastoid muscle (1). B, Local infiltration is also performed along the anterior border of the sternocleidomastoid muscle (2), and a local field block (3) is performed. Reprinted with permission from *Minimally Invasive Endocrine Surgery*.¹¹ Copyright 2002, Lippincott Williams & Wilkins.

Table 1. Clinical Data on 441 Patients With Primary Hyperparathyroidism Undergoing Minimally Invasive Parathyroidectomy

Characteristic	Mean \pm SEM*
Age, y	57.6 \pm 0.01
Male/female, No.	116/325
Preoperative serum calcium level, mg/dL†	11.4 \pm 0.001
Preoperative serum PTH level, ng/L‡	145 \pm 0.001

Abbreviation: PTH, parathyroid hormone.

SI conversion factor: To convert serum calcium to micromoles per liter, multiply by 0.25.

*Unless otherwise indicated.

†Reference range, 8.8 to 10.2 mg/dL (2.20-2.60 mmol/L).

‡Reference range, 10 to 65 ng/L.

Table 2. Reasons for Conversion From Cervical Block to General Anesthesia During Minimally Invasive Parathyroidectomy in 441 Consecutive Patients

Indication	No (%) (N = 47)
Concomitant thyroid pathologic features	16 (34.0)
Multiglandular parathyroid hyperplasia	15 (31.9)
Technical consideration	8 (17.0)
Patient discomfort	5 (10.6)
Intraoperative diagnosis of parathyroid carcinoma	2 (4.3)
Toxic reaction to lidocaine	1 (2.1)

erotropic transplantation of parathyroid tissue to the non-dominant forearm or a subtotal parathyroidectomy leaving a well-vascularized parathyroid remnant in situ are appropriate operations.

Parathyroid surgery is a meticulous procedure and operative experience correlates to rates of recurrence, persistence, and complications. Standard bilateral cervical exploration, when performed by experienced surgeons, has a cure rate exceeding 95%.^{3,10,11}

Because of the advancements in preoperative localization, availability of intraoperative PTH measurement, and the fact that most patients with primary HPT

have a unilateral parathyroid adenoma, a number of MIP techniques have been developed and are likely to replace the conventional bilateral cervical exploration in the majority of patients.^{5,7-9,13,14}

In 441 consecutive patients, we analyzed the reason for conversion from cervical block to general anesthesia. In all instances, conversion was performed in a controlled fashion using neuromuscular blockade, endotracheal intubation, and maintenance of the original surgical field preparation. The most common reason was unrecognized concomitant thyroid pathologic features. This rate corresponds to those previously reported in the literature.¹⁵ In 15 cases, the intraoperative PTH level failed

to adequately decline, suggesting remaining hyperfunctioning parathyroid tissue. Indeed, in all patients, additional hyperfunctioning parathyroid tissue was identified, with subsequent normalization of serum PTH levels. Eight procedures were converted because of technical difficulties related to ensuring adequate protection of the recurrent laryngeal nerve. The anatomy of the recurrent laryngeal nerve can vary significantly between patients. In rare cases, a formal nerve dissection must be performed dissecting 1 or more branches off the parathyroid adenoma. Usually, this can be accomplished using cervical block anesthesia. However, we have encountered patients who had both a technically difficult nerve dissection and were uncomfortable lying still on the operating table. Under such circumstances, we elected to convert to general endotracheal anesthesia to ensure a safe dissection. Five cases underwent conversion because of subjective claustrophobia experienced by the patient. Importantly, in 2 cases, parathyroid carcinoma was diagnosed intraoperatively. Conversion to bilateral standard cervical exploration is beneficial in such cases to ensure adequate en bloc resection and ipsilateral hemithyroidectomy.^{3,10,16} The suspicion of parathyroid carcinoma is the responsibility of the operating surgeon based on intraoperative findings of a large, firm parathyroid gland that appears to invade the surrounding structures. This occurred in the 2 cases that were converted to general endotracheal anesthesia. In each case, permanent histopathologic diagnosis confirmed the diagnosis and demonstrated a complete resection. One patient experienced a toxic reaction to lidocaine, causing a seizure.

Overall, the cure rate was 95.7% in patients requiring conversion to GA, which is slightly lower than the previously reported cure rate of 99% for MIP at our institution. The lower cure rate in this population is not surprising, however, because these cases represent the most challenging subset of patients, who by definition could not be cured using the standard MIP technique.

The advantage of cervical block anesthesia vs GA relates to the decreased operating time, costs, and need for oral pain medication.^{5,8} Additionally, endotracheal intubation by itself has been associated with objective functional voice changes in as much as 5% of patients.¹⁷

In conclusion, the vast majority of MIPs can be performed using cervical block anesthesia. However, conversion to GA is appropriate when unexpected intraoperative findings are encountered or for patient comfort.

Accepted for Publication: December 1, 2005.

Correspondence: Robert Udelsman, MD, MBA, Department of Surgery, Yale University School of Medicine, 330 Cedar St, FMB 102, Box 208062, New Haven, CT 06510 (robert.udelsman@yale.edu).

Previous Presentation: This paper was presented at The 86th Annual Meeting of the New England Surgical Society; October 1, 2005; Bretton Woods, NH; and is published after peer review and revision. The discussions that follow this article are based on the originally submitted manuscript and not the revised manuscript.

REFERENCES

1. Lundgren E, Rastad J, Åkerström G, Ljunghall S. Population-based health screening for primary hyperparathyroidism with serum calcium and parathyroid hormone values in menopausal women. *Surgery*. 1997;121:287-294.
2. Carling T. Molecular pathology of parathyroid tumors. *Trends Endocrinol Metab*. 2001;12:53-58.
3. Carling T, Udelsman R. Advancements in the surgical treatment of primary hyperparathyroidism. *Problems in General Surgery*. 2003;20:31-37.
4. Udelsman R, Donovan PI, Sokoll LJ. One hundred consecutive minimally invasive parathyroid explorations. *Ann Surg*. 2000;232:331-339.
5. Udelsman R. Six hundred fifty-six consecutive explorations for primary hyperparathyroidism. *Ann Surg*. 2002;235:665-670.
6. Udelsman R. Surgery in primary hyperparathyroidism: the patient without previous neck surgery. *J Bone Miner Res*. 2002;17(suppl 2):N126-N132.
7. Chen H, Mack E, Starling JR. Radioguided parathyroidectomy is equally effective for both adenomatous and hyperplastic glands. *Ann Surg*. 2003;238:332-337, discussion 337-338.
8. Miccoli P, Barelioni L, Monchik JM, Rago R, Berti PF. Randomized clinical trial comparing regional and general anaesthesia in minimally invasive video-assisted parathyroidectomy. *Br J Surg*. 2005;92:814-818.
9. Miccoli P. Parathyroid surgery: we only need a minimal surgical approach. *J Endocrinol Invest*. 2005;28:570-573.
10. Carling T, Udelsman R. Parathyroid tumors. *Curr Treat Options Oncol*. 2003;4:319-328.
11. Udelsman R. Unilateral neck exploration under local or regional anesthesia. In: Gagner M, Inabnet W III, eds. *Minimally Invasive Endocrine Surgery*. Vol 1. Philadelphia, Pa: Lippincott Williams & Wilkins; 2002.
12. Irvin GL III, Molinari AS, Figueroa C, Carneiro DM. Improved success rate in re-operative parathyroidectomy with intraoperative PTH assay. *Ann Surg*. 1999;229:874-878, discussion 878-879.
13. Henry JF, Jacobone M, Mirallie E, Deveze A, Pili S. Indications and results of video-assisted parathyroidectomy by a lateral approach in patients with primary hyperparathyroidism. *Surgery*. 2001;130:999-1004.
14. Bergenfelz A, Lindblom P, Tibblin S, Westerdaal J. Unilateral versus bilateral neck exploration for primary hyperparathyroidism: a prospective randomized controlled trial. *Ann Surg*. 2002;236:543-551.
15. Prinz RA, Barbato AL, Braithwaite SS, et al. Simultaneous primary hyperparathyroidism and nodular thyroid disease. *Surgery*. 1982;92:454-458.
16. Carling T, Udelsman R. Parathyroid surgery in familial hyperparathyroid disorders. *J Intern Med*. 2005;257:27-37.
17. Stojadinovic A, Shaha A, Orlikoff R, et al. Prospective functional voice assessment in patients undergoing thyroid surgery. *Ann Surg*. 2002;236:823-832.

DISCUSSION

Jack Monchik, MD, Providence, RI: In looking at your data, the great majority of patients had thyroid surgery that required conversion. In Providence, we've been using bilateral cervical block as described by LoGerfo, and this has enabled us to do thyroid surgery. At the same time, it also enables you, when the PTH assay does not drop appropriately, to easily look at the other side.

Dr Carling: Usually we start out with an ipsilateral cervical block; however, as you mentioned, that can easily be done as a contralateral block as well, and in many instances, we do continue the operation without conversion to general anesthesia but with a bilateral exploration.

Thomas Tracy, MD, Providence: It seemed as though you had a very low percentage of patient discomfort as the cause of conversion. Do you have 1 team of anesthesiologists doing this all the time?

Dr Carling: Yes, that's correct. Dr Rinder is the anesthesiologist who does the vast majority of these cases, and I think the key is to have a good understanding of the procedure from an anesthesia point of view as well as communication between the surgeon and anesthesiologist.